

Case Report Dental Implants

A novel root analogue dental implant using CT scan and CAD/CAM: selective laser melting technology

M. Figliuzzi¹, F. Mangano²,
C. Mangano³

¹Dental School, University of Catanzaro, Catanzaro, Italy; ²Private Practice, Gravedona (Como), Italy; ³Dental School, University of Varese, Varese, Italy

M. Figliuzzi, F. Mangano, C. Mangano: A novel root analogue dental implant using CT scan and CAD/CAM: selective laser melting technology. Int. J. Oral Maxillofac. Surg. 2012; xxx: xxx–xxx. © 2012 International Association of Oral and Maxillofacial Surgeons. Published by Elsevier Ltd. All rights reserved.

Abstract. Direct laser metal forming (DLMF) is a new technique which allows solids with complex geometry to be produced by annealing metal powder microparticles in a focused laser beam, according to a computer-generated three-dimensional (3D) model. For dental implants, the fabrication process involves the laser-induced fusion of titanium microparticles, in order to build, layer by layer, the desired object. Modern computed tomography (CT) acquisition and 3D image conversion, combined with the DLMF process, allows the fabrication of custom-made, root-analogue implants (RAI), perfect copies of the radicular units that need replacing. This report demonstrates the successful clinical use of a custom-made, root-analogue DLMF implant. CT images of the residual non-restorable root of a right maxillary premolar were acquired and modified with specific software into a 3D model. From this model, a custom-made, root-analogue, DLMF implant was fabricated. Immediately after tooth extraction, the root-analogue implant was placed in the extraction socket and restored with a single crown. At the 1-year follow-up examination, the custom-made implant showed almost perfect functional and aesthetic integration. The possibility of fabricating custom-made, root-analogue DLMF implants opens new interesting perspectives for immediate placement of dental implants.

Keywords: immediate implants; primary stability; direct laser metal forming; custom-made root-analogue implants.

Accepted for publication 18 January 2012

Immediate implants are implants inserted immediately after surgical extraction of the teeth to be replaced². The idea underpinning immediate implant placement is to preserve the alveolar height and width, reducing the marginal bone resorption that typically follows extraction socket healing². The advantages of immediate

implantation include shortening of the rehabilitation treatment time and the avoidance of a second surgical intervention¹. There are some disadvantages related to immediate implant placement in fresh alveolar sockets².

Primary stability represents a fundamental pre-requisite for osseointegration

and in a fresh extraction socket it can be difficult to achieve². As adequate bone quantity and quality are essential prerequisites for achieving primary implant stability, the surgical requirements for immediate implantation include extraction with the least trauma possible and the careful preservation of the alveolar socket

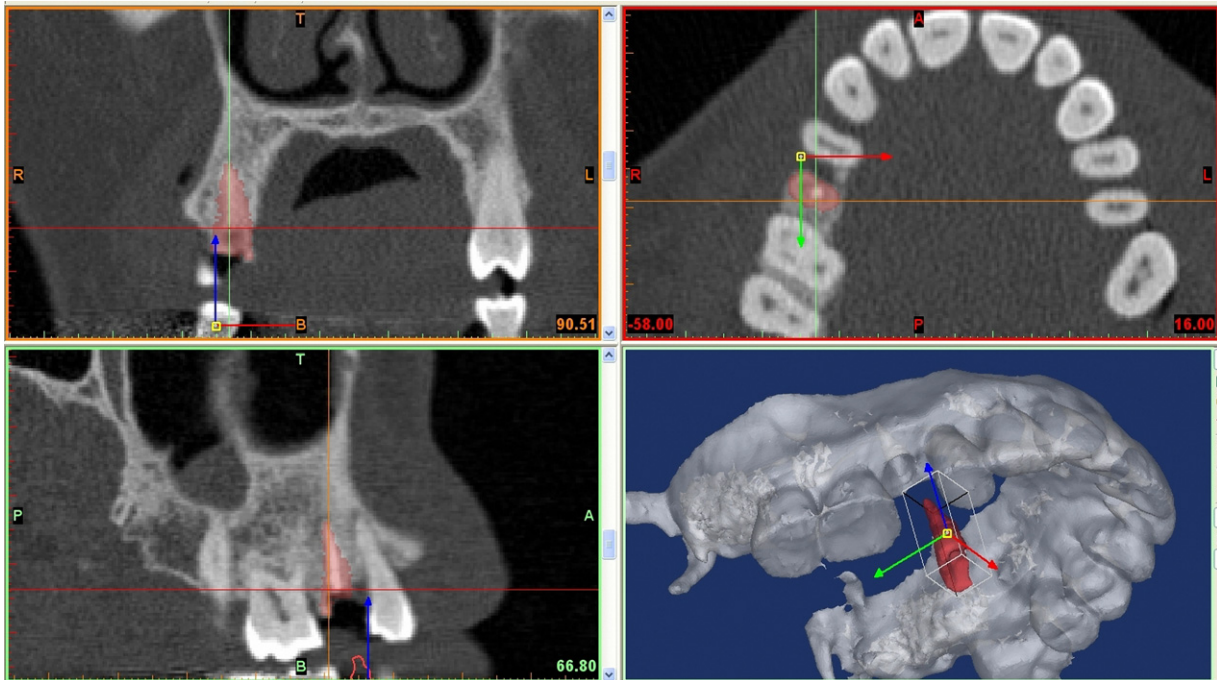


Fig. 1. 3D projection of the maxilla and the residual root, with the 'virtual' extraction of the root.

walls. Primary implant stability seems to be related to the implant macroscopic features (shape, length and diameter). Until now, primary implant stability in fresh post-extraction sockets has been achieved by placing implants exceeding the alveolar apex by 3–5 mm, or by inserting implants of greater diameter than the remnant alveolus^{2,6}.

One possible alternative to the traditional threaded, straight or tapered implant systems intended to replace a missing tooth is the fabrication of a customized, dental root-analogue implant (RAI)^{6,10}. Few studies describing the techniques of creating and placing custom-made RAI have been noted in the literature^{3,4,6–10}. In the last few years, considerable progress has been made in the development of rapid prototyping (RP) methods, including direct laser metal forming (DLMF)^{6,5}. DLMF is a timesaving procedure in which a high power laser beam is directed on a metal powder bed and programmed to fuse particles according to a computer assisted design (CAD) file, generating a thin metal layer. Apposition of subsequent layers gives shape to a desired 3D form with minimal post-processing requirements⁵. With DLMF it is possible to fabricate dental implants of different size and shape, directly from CAD models⁵.

Modern computed tomography (CT) acquisition and 3D image conversion, combined with the DLMF process, allows the fabrication of custom-made RAI, which are perfect copies of the radicular

units to be replaced⁶. Perfect implant fit could lead to excellent primary stability, however, it might be responsible for the intermediate term failure, because of the subsequent uniform pressure-induced resorption concerning the entire alveolar surface^{4,8,9} simultaneously affecting the thin buccal layer, which is prone to fracture and pressure-induced resorption^{4,8,9}.

The aim of the present study was to demonstrate how new DLMF technologies permit the fabrication of a custom-made, titanium RAI, which can be predictably inserted in a fresh extraction socket, with immediate restoration.

Case study

A 50-year-old healthy female patient with a fractured non-restorable second maxillary right premolar was selected for this study. The patient gave consent for implant therapy. This study was performed according to the principles outlined in the World Medical Association's Declaration of Helsinki on experimentation involving human subjects, as revised in 2008.

Implant fabrication

CT datasets of the fractured tooth were acquired using a modern cone beam scanner (Verawiewpocs 3D^R, Morita Corporation, Tokyo, Japan). CT datasets were transferred in the DICOM format to specific 3D reconstruction software (Mimics^R, Materialise, Leuven, Belgium).

With this software, it was possible to construct a 3D projection of the maxilla and the residual root, simulating a 'virtual' extraction of the root (Fig. 1). The root was isolated as a stereolithographic (STL) file and transferred to proprietary reverse-engineering software (Leader-Novaxa^R, Milan, Italy). The root was smoothed to obtain a regular surface. The STL file was returned to the 3D reconstruction software (Mimics^R, Materialise, Leuven, Belgium), to test the congruence between the root and the alveolar socket. The file was transferred to Pro/Engineering CAD 3D software (PTC Group^R, Needham, MA, USA) where a prosthetic conical abutment was designed, and a reduction of the diameter of the implant neck next to the thin vestibular cortical bone was made (Fig. 2). With the aid of another 3D image reconstruction programme (Magics^R, Materialise, Leuven, Belgium), copies of the final STL file (virtual root plus abutment) were prepared, with sequential percentage dimensional increments, in order to provide the surgeon with three different STL files representing different size increments (0%, 5%, 10%) of the same object (to avoid potential distortions or errors related to the 3D projection steps). All three STL copies were used to manufacture the implants using the DLMF technique (Leader-Novaxa^R, Milan, Italy)^{9,5}. The implants were made of Ti-6Al-4V alloy powder, with a particle size of 25–45 μm as the basic material. Processing was carried out in an argon atmosphere using a



Fig. 2. The STL file of the custom-made RAI.

powerful ytterbium (Yb) fibre laser system (Eos Laser Systems^R, Munich, Germany) with the capacity to build a volume up to 250 mm × 250 mm × 215 mm using a wavelength of 1054 nm with a continuous power of 200 W, at a scanning rate of 7 m/s. The size of the laser spot was 0.1 mm. This procedure allowed the creation of three incremental custom-made

titanium implants, perfect copies of the natural root, with integral abutments. To remove residual particles from the manufacturing process, the implants were sonicated for 5 min in distilled water at 25 °C, immersed in NaOH (20 g/l) and hydrogen peroxide (20 g/l) at 80 °C for 30 min, and then sonicated for 5 min in distilled water. Acid etching was carried out by immersion

of the samples in a mixture of 50% oxalic acid and 50% maleic acid at 80 °C for 45 min, followed by washing for 5 min in distilled water in a sonic bath. The implants were packaged in custom-made disposable packaging fabricated with the aid of specific software (Pro/Engineering CAD 3D^R, PTC, Needham, MA, USA).

Surgical and prosthetic procedure

Local anaesthesia was obtained by infiltrating articaine 4% containing 1:100,000 adrenaline. Surgical access was obtained in a conservative manner by an intrasulcular incision, and the second maxillary right premolar was extracted carefully avoiding any damage to the socket and soft tissue. The loss of one of the cortical walls could compromise the correspondence between the custom-made implant and the socket, reducing primary stability, thus jeopardizing the final result of the treatment. The extraction socket was debrided carefully by means of curettage. After that, the RAI (0%) was placed in the socket under finger pressure and subsequent gentle tapping with a hammer and a mallet. Primary stability was achieved as checked by palpation and percussion, due to the perfect correspondence between the custom-made implant and the post-extraction socket. At the end of the surgical procedure, interrupted sutures were positioned and a provisional single crown was cemented on the abutment of the custom-made implant.

The provisional restoration was taken out of any functional occlusal contacts both in centric occlusion and during excursive mandibular movements, and the patient was instructed to chew predominantly on the contralateral side and avoid hard food. The patient received dexketoprofene 25 mg 2 times/day as a postoperative analgesic. Antibiotic therapy with amoxicillin and clavulanic acid 1 g 2 times/day was also administered and maintained for 6 days. The patient was seen on a weekly basis during the first 4 weeks. At the first control visit, 7 days after the surgery, a clinically healthy marginal area was present and no postoperative pain or swelling was reported. There was no bleeding or wound infection. Sutures were removed. After 2 weeks, the peri-implant tissues showed good marginal adaptation. After 3 weeks, the peri-implant tissues were stable and in optimal condition. The provisional restoration was maintained *in situ* for 3 months, after that the definitive restoration was placed. The definitive restoration was a cemented, all-ceramic single crown.

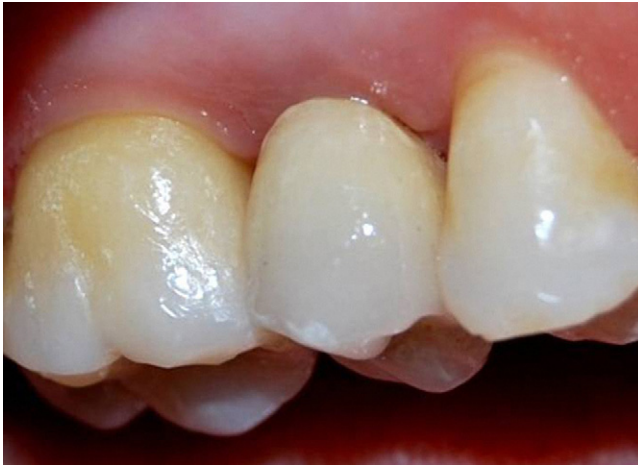

Fig. 3. The definitive restoration *in situ* 1 year after implant placement.

Results

One year after placement, the custom-made implant was still in function (Fig. 3). The implant was stable, with no signs of infection, such as pain or suppuration. The good conditions of the peri-implant tissues were confirmed by the radiographic examination, with unchanged peri-implant marginal bone level and no peri-implant radiolucency (Fig. 4). The radiographic profile of the implant–crown complex was very similar to that of natural tooth. No prosthetic complications occurred. The prosthetic restoration showed optimal functional and aesthetic integration.

Discussion

Implant dentistry has evolved toward simplification of clinical procedures and

shortened treatment times, with such developments as immediate implant placement². Primary stability is of paramount importance with immediate implantation, and a good fit between the implant and the host bed is an important factor for implant success². For this reason, it could be an advantage to design a dental implant according and congruent to the individual extraction socket. Hodosh et al.¹ were the first to use a custom-made RAI placed into the extraction socket, reducing bone and soft tissue trauma. The polymethacrylate tooth-analogue was encapsulated by soft tissue rather than osseointegrated¹. Animal studies with root-identical titanium implants yielded extremely favourable results with clear evidence of osseointegration⁴. In several instances implant insertion led to fractures of the thin buccal wall of the alveolar bone^{3,4}. A subsequent clinical study revealed excellent primary

stability, but with a high disappointing failure rate of 48% at 9 months' follow-up³. Owing to this high failure rate, the use of these titanium RAI was not recommended for clinical use³. In a recent clinical study, however, the immediate placement of a non-submerged zirconia RAI with macro-retention in the interdental space and a diameter reduction of 0.1–0.3 mm next to the buccal cortical bone yielded excellent functional and aesthetic results⁷. No clinically noticeable bone resorption or soft tissue recession was reported at the 2-year follow-up⁷. These results were confirmed in more recent clinical studies^{8,9}. The reduction of the diameter of the implant next to the thin cortical bone is important to avoid fracture and pressure-induced bone loss. Cortical bone covering the root is very thin with no, or few, blood vessels and is prone to fracture and pressure-induced resorption^{3,4,7–8}, a perfect fit of the implant in this area might be responsible for the aesthetic failure because of pressure-induced resorption^{3,4,7–9}. The presence of macro-retentions limited to the interdental space can improve primary implant stability and osseointegration^{6,8,9}. More recently, a novel approach to fabricate a custom-made RAI using a cone beam CT 3D model and CAD/CAM was proposed⁶. With the combined use of cone beam CT 3D data and high-end CAD/CAM technology it was possible to manufacture a RAI with sufficient precision⁶. Modern CT acquisition and 3D image conversion, combined with the DLMF process, allows the fabrication of custom-made RAI which are perfect copies of the radicular units needed for replacement⁶. In this study, a custom-made, DLMF, titanium RAI was placed into an extraction socket. A perfect congruence between implant and extraction socket was obtained, with a diameter reduction of 0.1–0.3 mm next to the buccal cortical bone. After 1 year of follow-up, the custom-made implant showed an almost perfect functional and aesthetic integration. The fabrication of custom-made RAI with the DLMF technique presents two distinct advantages. The DLMF technique allows the fabrication of functionally graded titanium implants, with a relatively high porosity at the surface and a high density in the core⁵. This type of modulation may allow better load adaptation, avoiding stress-shielding and pressure-induced bone loss⁵. With DLMF, a porous surface is obtained, capable of accelerating the healing processes and promoting osseointegration⁵. The possibility of fabricating custom-made, DLMF RAI opens new interesting perspectives for immediate placement of dental implants.

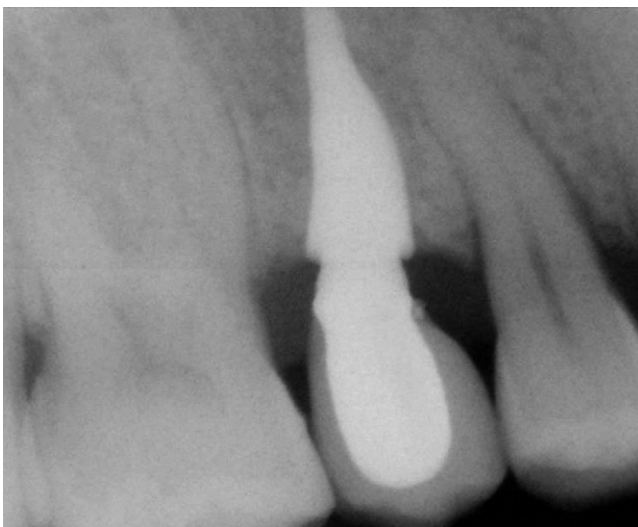


Fig. 4. X-ray at 1-year follow-up with the custom-made RAI and crown *in situ*.

Acknowledgements. The authors are grateful to Rachel Sammons, PhD, Senior Lecturer, Dental School, University of Birmingham, UK, and to Leonzio Fortunato, DDS, Dental School, University of Catanzaro, Italy, for help with writing the manuscript.

Competing interests: None.

Funding: No grants, equipment, or other sources of support were provided for this work.

Ethical approval: No ethical approval was required.

References

- Hodosh M, Povar M, Shklar G. The dental polymer implant concept. *J Prosthet Dent* 1969;**22**:371–80.
- Koh R, Rudek I, Wang HL. Immediate implant placement: positives and negatives. *Implant Dent* 2010;**19**:98–108.
- Kohal RJ, Klaus G, Strubl JR. Clinical investigation of a new dental immediate implant system. The reimplant-system. *Dtsch Zahnarztl Z* 2002;**57**:495–7.
- Lundgren D, Rylander H, Andersson M, Johansson C, Albrektsson T. Healing-in of root analogue titanium implants placed in extraction sockets. An experimental study in the beagle dog. *Clin Oral Implants Res* 1992;**3**:136–44.
- Mangano C, Mangano F, Shibli JA, Ricci M, Perrotti V, d'Avila S, Piattelli A. Immediate loading of mandibular overdentures supported by unsplinted direct laser metal forming (DLMF) implants. Results from a 1-year prospective study. *J Periodontol* 2012;**83**:70–8.
- Moin DA, Hassan B, Mercelis P, Wismeijer D. Designing a novel dental root analogue implant using cone beam computed tomography and CAD/CAM technology. *Clin Oral Implants Res* 2011. [10.1111/j.1600-0501.2011.02359.x](https://doi.org/10.1111/j.1600-0501.2011.02359.x). November 14 [Epub ahead of print].
- Pirker W, Kocher A. Immediate, non-submerged, root-analogue zirconia implant in single tooth replacement. *Int J Oral Maxillofac Surg* 2008;**37**:293–5.
- Pirker W, Kocher A. Immediate, non-submerged, root-analogue zirconia implants placed into single-rooted extraction sockets: 2-year follow-up of a clinical study. *Int J Oral Maxillofac Surg* 2009;**38**:1127–32.
- Pirker W, Wiedemann D, Lidauer A, Kocher A. Immediate, single stage, truly anatomic zirconia implant in lower molar replacement: a case report with 2.5 years follow-up. *Int J Oral Maxillofac Surg* 2011;**40**:212–6.
- Sharma KMR, Drp D. An overview of immediate root analogue zirconia implants. *J Oral Implantol* 2011. September 9 [Epub ahead of print].

Address:

Francesco Mangano
Piazza Trento 4
22015 Gravedona (Como)
Italy
Tel.: +39 0344 85524
fax: +39 0344 85524
E-mail: francescomangano1@mcmlink.net